

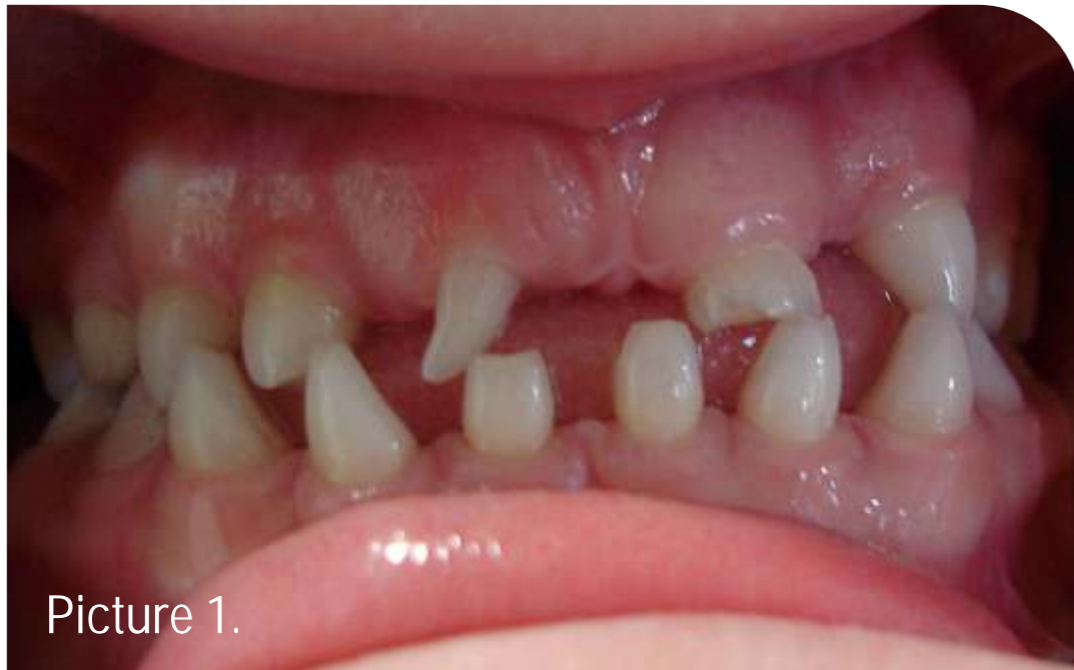

United Medical

Private Clinic, Plovdiv, Bulgaria

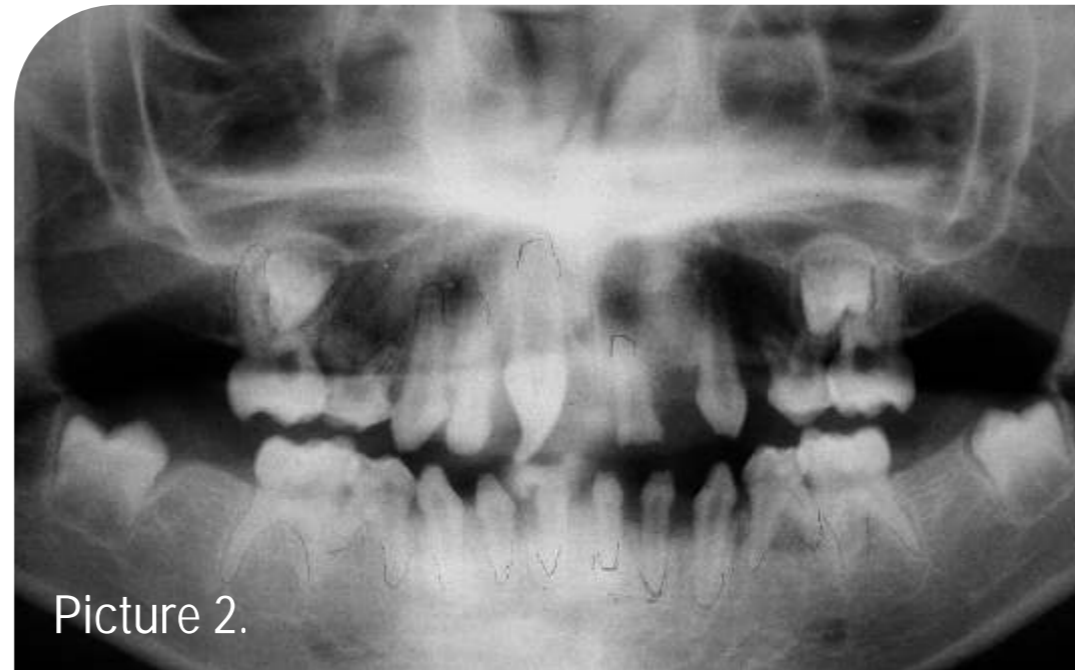
Dental treatment of a child with Ectodermal dysplasia – a case report

Em. Ilieva , D. Geordgeva , V. Garabedian



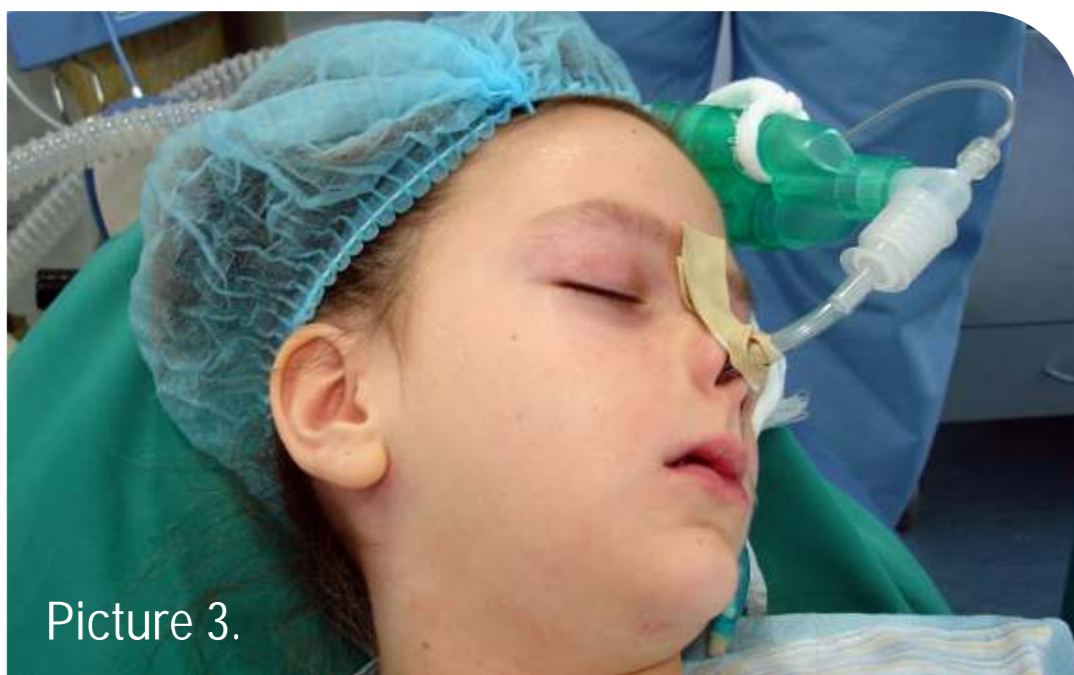Picture 1.

During intraoral examination primary dentition with a missing 52 tooth was noted; instead of a normal 61 a peg- shaped tooth with a pointed peak that leans to the distal side was observed. There is large spacing between the teeth and a diastema.



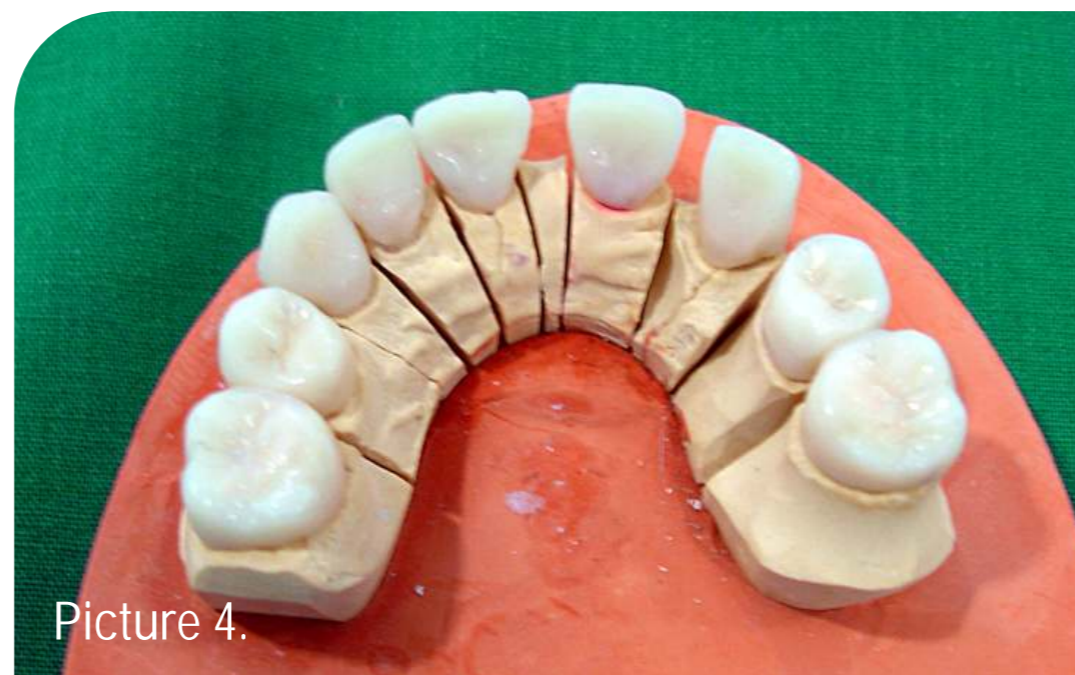Picture 2.

The panoramic radiography shows missing permanent teeth except for 11, 12, 17 and 27.



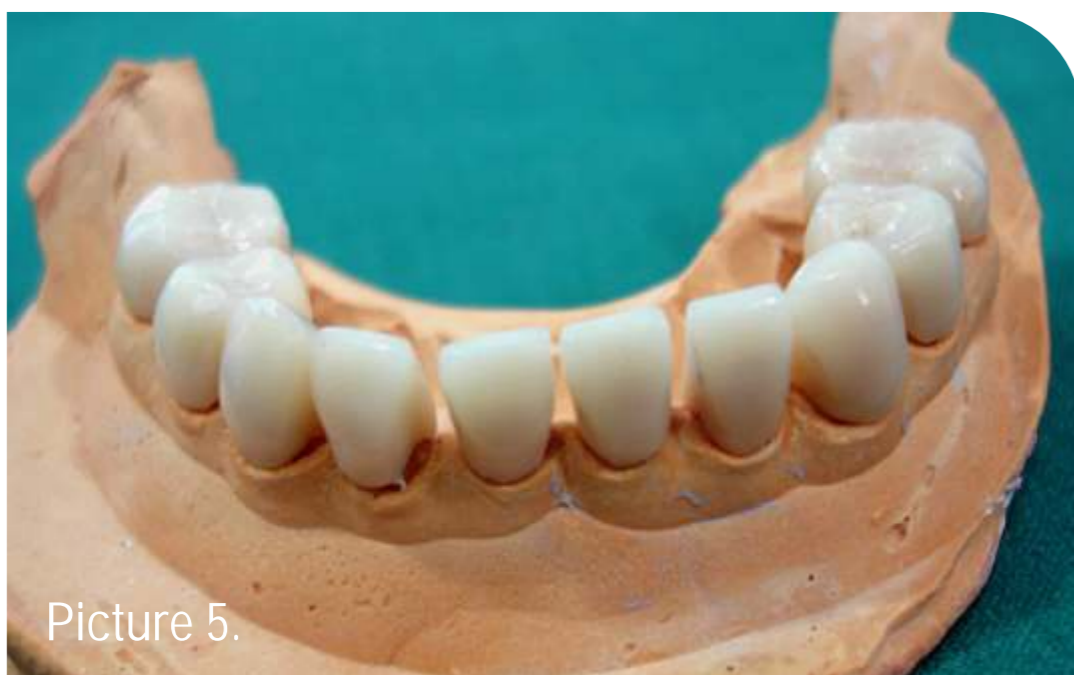Picture 3.

A behaviour management by applying general anaesthesia was chosen due to the fragile psyche of the patient. Nasotracheal intubation was applied.



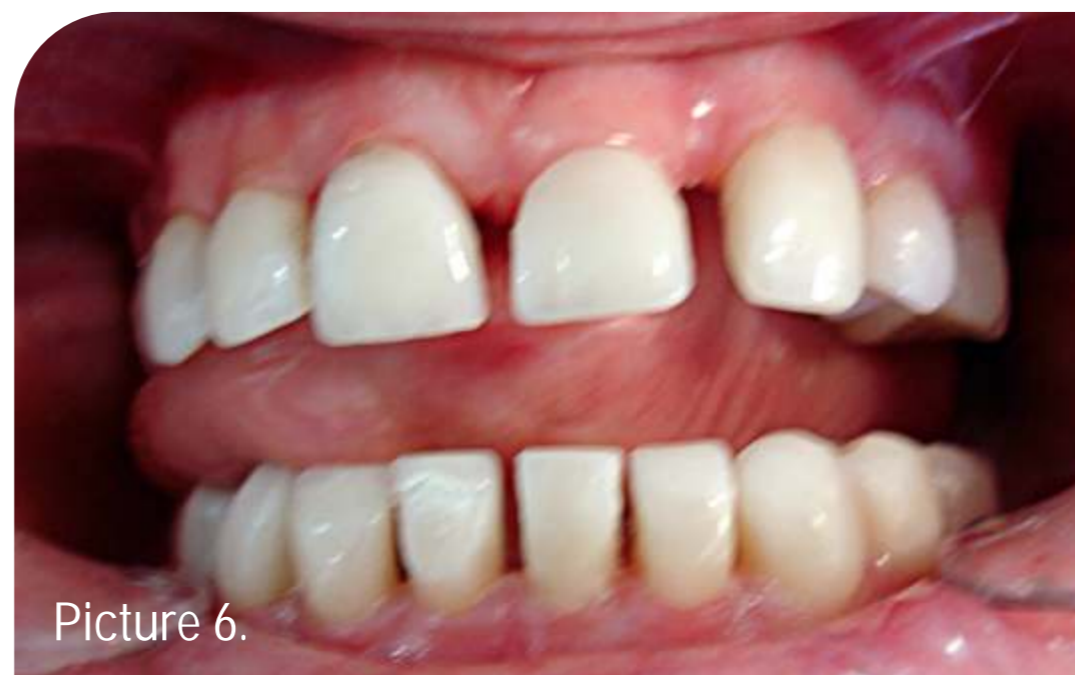Picture 4.

Fabricated specifically for the case composite resin crowns.



Picture 5.

Fabricated specifically for the case composite resin crowns.



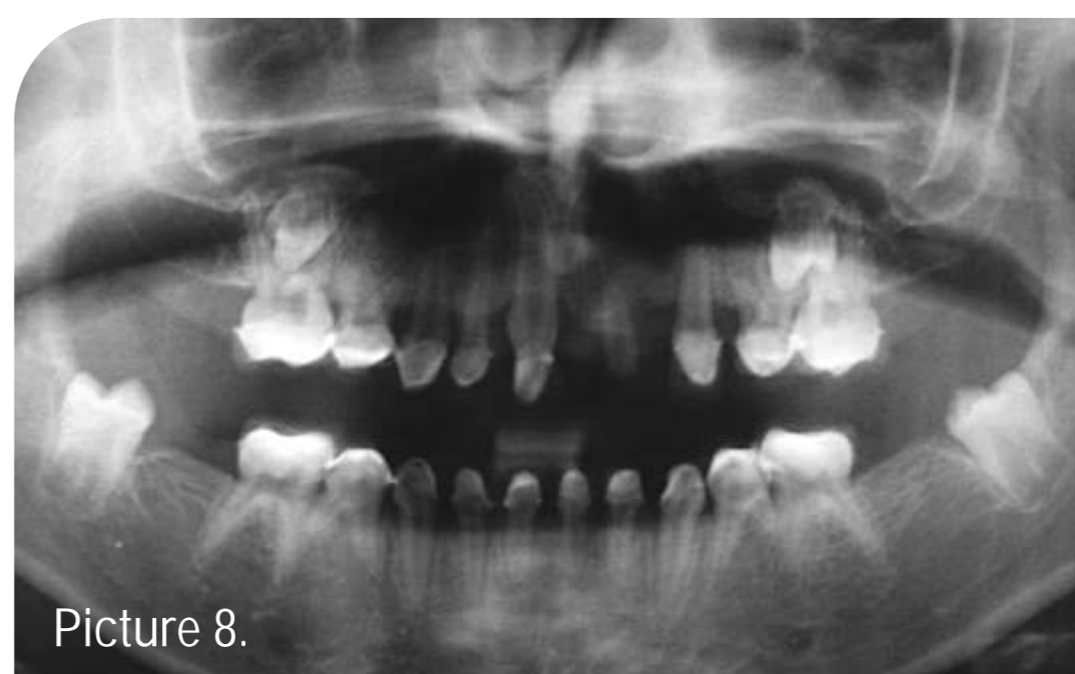Picture 6.

On the day of placement of the crowns.



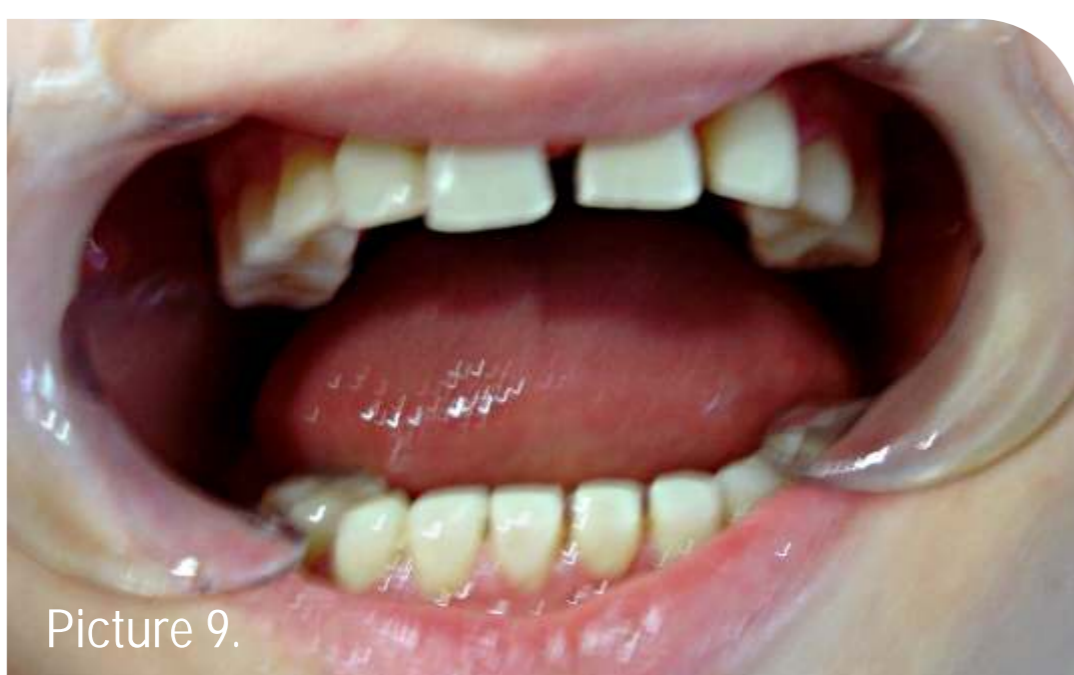Picture 7.

One month after the operation.




Picture 8.

The panoramic radiography a year later.



Picture 9.

The clinical exam a year later.



Picture 10.

A year after the replacement the patient has better aesthetics and function of the teeth and is more confident.

INTRODUCTION

The term ectodermal dysplasia comprises a large and heterogenous group of inherited disorders defined by primary defects in the development of two or more tissues that evolve from the embryonic ectoderm. Primarily involved organs include the skin, hair, nails, eccrine glands and teeth. Although the first case of ED was described by Thurman in 1848 the term was coined in 1929 by Weech. Currently there are about 150 different types of ectodermal dysplasia. In an attempt to classify these, different subgroups were created according to the presence or absence of the four main ED defects : Trichodysplasia (hair dysplasia), Dental dysplasia, Onychodysplasia (nail dysplasia) and Dyshidrosis (sweat gland dysplasia).

Frequency of different types of ED in any given population is highly variable. Prevalence of hypohidrotic ED, which is the most common variant is estimated to be 1 case per 100 000 births.

There are no medical data for Bulgaria.

DESCRIPTION OF THE CLINICAL CASE

The patient is M.D., an 8-year-old girl with X-linked hypohidrotic ED. She has reduced lower facial height and lip protrusion. The clinical exam has shown primary dentition with a missing 52 tooth. On the place of tooth 61 a peg-shaped tooth with a pointed peak turned to the distal side can be observed. The panoramic radiography analysis shows missing permanent teeth except 11, 12, 17 and 27.

The applied treatment includes: behaviour management (performed dental treatment under general anaesthesia) and prosthetic treatment with composite resin crowns (PEDO-Jacket crowns). The aim is to preserve the present primary teeth, to manage the deep overbite and improve the chewing and articulation processes.

One year later the panoramic radiographs show advanced root development of some of the permanent teeth; lack of change in the resorption level of the primary teeth; normal condition of the alveolar bone.

Due to shortened length of the clinical crown of tooth 61 a root canal treatment and the placement of a glass fibre composite post was necessary.

The patient has restored her confidence, smiles a lot more and has resumed studying at a regular school unlike prior to the treatment, when she had private tutors.

CONCLUSION

With patients that have hypo- or oligodontia an early prosthetic treatment is a must. Ongoing supervision and replacement of the prosthetic constructions will be needed during the growing of the child. A definitely prosthetic treatment can be performed after the patient has reached 18 years of age and if indications of implant placement are present.